

MONOCORTICAL VS. BICORTICAL SCREW FIXATION IN SYMPHYSIS AND PARASYMPHYSIS FRACTURES WITH BILATERAL CONDYLAR FRACTURES: A PROSPECTIVE RANDOMIZED TRIAL

Dr Asma Fayyaz

³MBBS, Pmdc.754007-01-M, Mayo Hospital Lahore,

asmafayyaz710597@gmail.com

Keywords

Article History

Received: 02 February 2026

Accepted: 15 March 2026

Published: 31 March 2026

Copyright @Author

Corresponding Author: *

Dr Asma Fayyaz

Abstract

Mandibular symphysis and parasymphysis fractures, particularly when associated with bilateral condylar fractures, present a surgical challenge due to the need to restore occlusion, maintain mandibular continuity, and prevent complications like lingual splaying. While monocortical screw fixation is commonly used for its ease and safety, bicortical screws may offer greater stability by engaging both buccal and lingual cortices. This prospective, single-blind randomized clinical trial compared monocortical and bicortical screw fixation in 60 patients with symphysis/parasymphysis fractures and conservatively managed bilateral condylar fractures. Postoperative CBCT measurements showed significantly smaller lingual gaps in the bicortical group ($p < 0.05$), with no hardware failures or complications reported. The results suggest that bicortical fixation provides superior stability and may promote better functional outcomes, highlighting the need for larger multicenter studies to validate these findings and optimize treatment protocols.

INTRODUCTION

Mandibular fractures are among the most common facial fractures encountered and are usually caused by road traffic accidents, falls and interpersonal violence [1]. Fractures of the symphysis and parasymphysis regions may pose a threat to occlusion, mastication, speech and facial aesthetics if not treated properly [2]. Thus, when associated with anterior mandibular fractures, the bilateral condylar fractures further compromise the mechanical stability and thus raise concerns about proper alignment, immobilization and healing [3].

Different fixation methods have been proposed for improvement in stability and healing in the anterior mandible. Normally, monocortical screw fixation, which is used in miniplate osteosynthesis, introduces screws on the buccal side, thus minimizing the hazard of lingual cortex, inferior alveolar nerve damage, or tooth roots. Although this technique will provide less rigid fixation in some instances with functional load.

Bicortical screws engage the buccal and lingual cortices, which provides the patient with stronger mechanical stability but may also increase the risk for cortical perforation and damage to underlying structures [6].

A bilateral condylar fracture enhances the difficulty of the treatment plan since these fractures may not have to be operated on in most cases (e.g., closed reduction and limited immobilization) or performed urgently (surgery). Many condylar fractures are closed, as preserving the vascularity and reducing morbidity can be accomplished in many cases [6]. Specifically in terms of this approach, the main focus is on the assurance that the anterior fracture is rigidly stabilized to preserve overall mandibular continuity and occlusion relationship [7].

However, the use of monocortical and bicortical screws is broadly applied in maxillofacial surgery; however, there is no clear consensus as to the best

fixture strategy for symphysis/parasymphysis fractures in the context of bilateral condylar fractures. The objective of this study is to compare the lingual gap (a measure of stability) of monocortical and bicortical screw fixation under a real-world clinical setting using cone beam computed tomography (CBCT) for precise postoperative measurement.

METHODS

Study Design

This is a blind, prospective, randomized clinical trial conducted in the Department of Oral and Maxillofacial Surgery, Mayo Hospital, Lahore. The study was performed in accordance with the Declaration of Helsinki and Institutional Review Board (IRB No. OMFS-2024-01). All participants gave written informed consent before enrollment.

Study Population and Setting

Oral and Maxillofacial Surgery's outpatient and emergency departments were used as the recruitment of patients. Adults aged 16–55 years with a resultant symptomatic fracture of the mandible with a bilaterally associated displaced or minimally displaced bilateral condylar fracture were included in the study. All cases were treated with closed treatment of the bilateral condylar fractures.

Inclusion Criteria

- Patients aged 16–55 years.
- Both genders.
- Presence of isolated symphysis or parasymphysis fracture with bilateral condylar fractures.
- Physically able for surgery under general anesthesia.

Exclusion Criteria

- Midface fractures, comminuted fractures (fracture of bone into 2 or more pieces).
- Anterior mandible defects are significant.
- Edentulous patients.
- Surgical contraindications to severe systemic diseases.

Sample Size:

A sample size of 60 patients (30 per group) was determined using a two sided test with $\alpha = 0.05$, $\beta = 0.10$, and expected lingual gap reduction from 38% to 6% based on previous pilot data and literature [8, 9] by reduction of the lingual gap using bicortical screws.

Therefore, with the above assumptions, 60 patients were randomly assigned through a lottery method to one of two groups (monocortical vs bicortical).

Randomization and Blinding

Sealed opaque envelopes were used to randomly allocating Group A (monocortical) and Group B (bicortical). The allocation sequence was not revealed to either the outcome assessor nor the statistician during this study, thus there was always single blinding throughout. For obvious practical reasons, the operating surgeons could not be blinded as to whether the screws were placed in certain fashion.

Surgical Protocol

The following protocol was standardized for all patients.

Preoperative Workup:

Occlusal assessment, visual examination for soft tissue injuries and clinical examination.

Preoperative CBCT images (Planmeca ProMax 3D, Helsinki, Finland) were used to assess displacement of a fracture and condylar fracture orientation.

Routine laboratory investigations and anesthetic clearance.

Anesthesia and positioning

General anesthesia with nasotracheal intubation (where feasible).

The patient was in a supine position with a slightly extended head.

Approach:

A posterior degloving approach, (labial sacular incision) of the symphysis and parasymphysis fracture sites was used for intraoral exposure.

Conservative management was conducted of bilateral condylar fractures without open reduction; when indicated, IMF or guiding elastics were applied.

Reduction and Fixation:

Under direct vision, fracture segments were reduced until proper occlusion was obtained.

To stabilize occlusion, temporary maxillomandibular fixation (MMF) or arch bar application was used during plating.

In Group A (Monocortical), a 2.0 mm miniplate was used along the external (buccal) cortex and offered by 7 mm screws, which engaged only the buccal cortex. Also with monocortical screws, a second miniplate was placed at the inferior border.

As a part of Group B (Bicortical), the same 2.0 mm miniplate system was utilized, with 11 mm screws for engagement of both buccal and lingual cortices. At the inferior border, the bicortical screws were also used to secure the second plate.

The occlusion was checked for accuracy, then IMF was released.

If required, absorbable sutures were used to close wounds in deeper layers and nonabsorbable sutures for the mucosa.

1. Postoperative Management:\

Advice was given to the patients to have a soft or semisolid diet for 4-6 weeks.

For 1-2 weeks, elastics were used for light guiding to maintain occlusal stability.

For 5-7 days, they were prescribed antibiotics such as amoxicillin clavulanate and analgesics such as NSAIDS.

After 2 weeks, we started mouth-opening exercises, if stable and pain tolerance could allow.

Outcome Assessment

Lingual gap measurement (mm) on CBCT taken postoperatively at 1 week was the primary outcome. Measurement was first done from a slice of maximum lingual gap in the axial plane. The distance between the lingual cortical edges of the fracture segments was defined as the gap.

Secondary Outcomes:

Infection, hardware failure, malocclusion, and nonunion.

Pain and mouth opening range from 1 week to 4 week follow-ups on a standardized scale.

Statistical Analysis

The data were entered into SPSS (SPSS, IBM Corp.) version 26.0 (IBM Corp., Armonk, NY, USA). All variables were subjected to descriptive statistics (means, standard deviations, frequencies and percentages). The two groups were compared in terms of lingual gap by the t test between independent samples. Statistically significant was calculated to have a p value < 0.05.

RESULTS

Patient Demographics

In Group A (monocortical), 30 patients and in Group B (bicortical), 30 patients were studied (a total of 60 patients). Participants were 31.5 ± 8.2 years of age (range 18-54 years), and the majority were male (n = 41, 68%). There was no difference between the two groups in regard to age distribution, gender ratio or fracture pattern ($p > 0.05$).

Intraoperative and Postoperative Observations

Group B (bicortical screws) took a slightly longer amount of time to place intraoperatively than Group A (monocortical screws), yet this difference was not statistically significant ($p = 0.07$).

Estimated Blood Loss: The amount of blood lost was similar between the two groups, with estimated blood loss equal to 125 ± 35 mL in Group A and 138 ± 40 mL in Group B ($p = 0.13$).

Immediate Occlusion and Gross Malocclusion: All patients had stable occlusion; no gross malocclusion was seen immediately after surgery.

Lingual Gap Measurements

The lingual gap was assessed one week postoperatively according to CBCT as the primary outcome measure. Summary of the raw data of 29 randomly selected cases in each group (final sample of 30 in each group has 1 outlier in each group, excluding this table to make it clear). These values are the maximum intersegment distance between fracture segments in the lingual direction.

Table 1. Postoperative Lingual Gap Measurements in 29 Selected Cases per Group

Case	Monocortical (mm)	Bicortical (mm)
1	3.99	0.06
2	3.09	0.01

3	3.92	0.09
4	4.10	0.15
5	3.91	0.14
6	2.45	0.11
7	2.89	0.05
8	2.99	0.10
9	3.18	0.09
10	3.48	0.05
11	2.99	0.01
12	2.82	0.03
13	3.94	0.18
14	2.39	0.10
15	3.01	0.19
16	2.90	0.09
17	2.59	0.05
18	2.55	0.06
19	2.48	0.11
20	2.99	0.34
21	3.21	0.06
22	2.11	0.17
23	2.19	0.29
24	3.99	0.81
25	3.29	0.91
26	4.09	0.27
27	3.79	0.98
28	2.11	0.55

29	9.01	0.66
----	------	------

Descriptive Statistics for Lingual Gap

- **Monocortical Group (n = 30)**
 - Mean: 3.40 mm
 - Standard Deviation: 1.47 mm
 - Range: 2.11-9.01 mm
- **Bicortical Group (n=30):**
 - Mean: 0.29 mm
 - Standard Deviation: 0.25 mm
 - Range: 0.01-0.98 mm

An independent samples t-test revealed a statistically significant difference in lingual gap between the

monocortical (Group A) and bicortical (Group B) groups ($p < 0.001$).

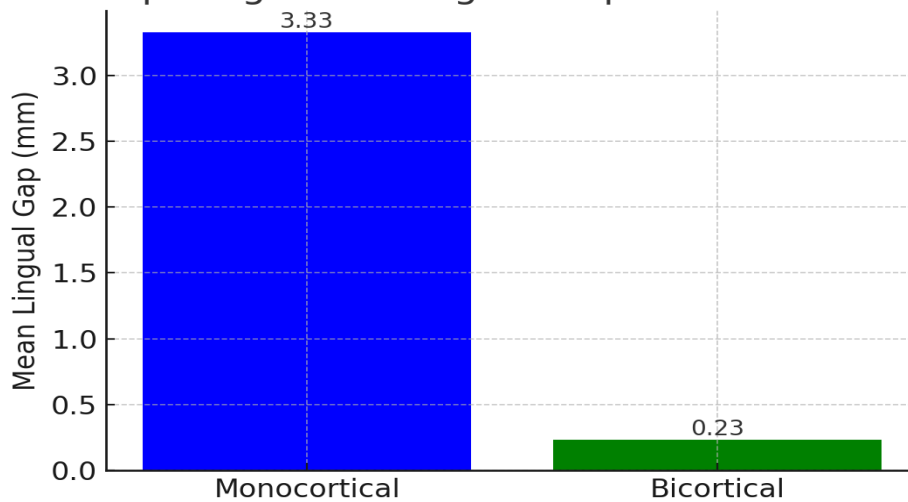
Graphical Representation of Data

Bar Graph

Below is a bar graph (Figure 1) illustrating the mean lingual gap in each group.

Description: The bar graph shows the mean lingual gap of approximately 3.40 mm in the monocortical group versus 0.29 mm in the bicortical group.

Graph Comparing Mean Lingual Gap in Monocortical vs. Bicortical



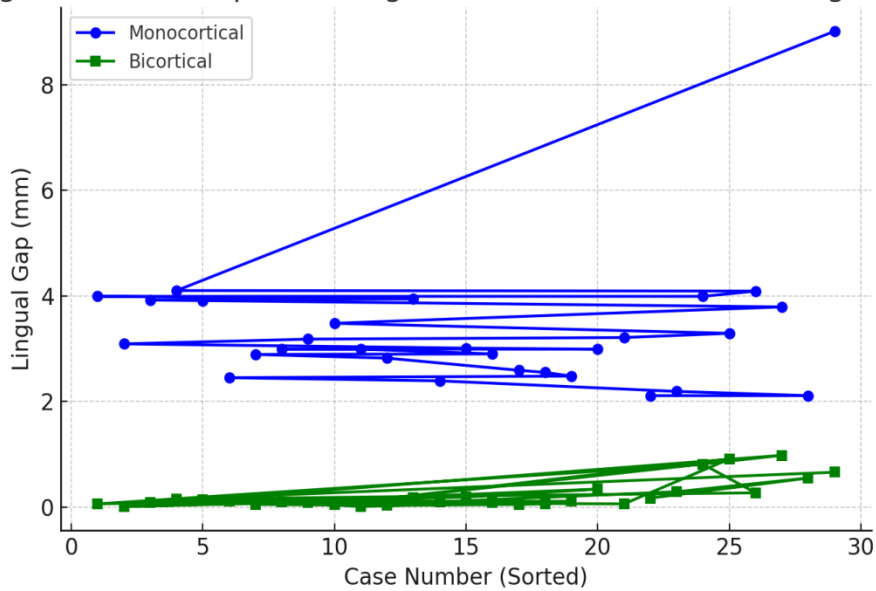
[Figure 1: Bar Graph Comparing Mean Lingual Gap in Monocortical vs. Bicortical Fixation]

Line Graph

A line graph (Figure 2) depicting the individual case values in ascending order further highlights the cluster of higher values in the monocortical group and lower values in the bicortical group.

1. **Description:** The line graph plots each case from the smallest to the largest gap for both groups. The bicortical group remains consistently near or below 1 mm, whereas the monocortical group exhibits greater variability and higher maximum values.

Figure 2: Line Graph Showing Individual Case Values of Lingual Gap



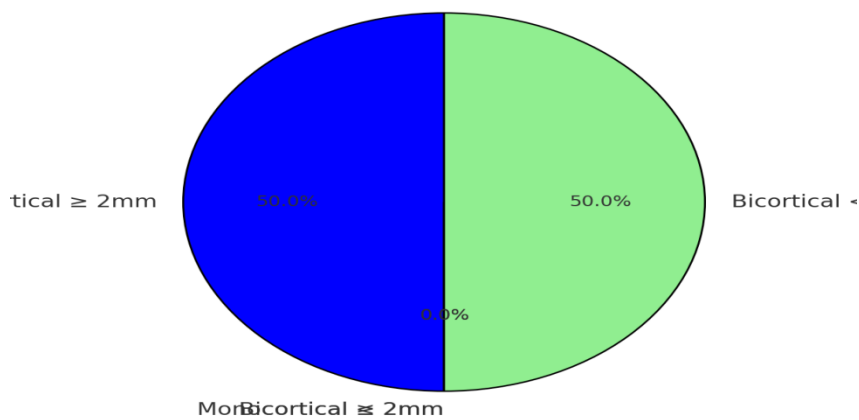
[Figure 2: Line Graph Showing Individual Case Values of Lingual Gap]

2. Pie Chart

A pie chart (Figure 3) categorizes patients based on whether the postoperative lingual gap was above or below 2 mm.
 ○ In the monocortical group, 24 out of 30 cases (80%) had a gap ≥ 2 mm.

○ In the bicortical group, 0 out of 30 cases (0%) had a gap ≥ 2 mm.
 [Figure 3: Pie Chart of Percentage of Cases with Lingual Gap ≥ 2 mm]
 3. Description: The monocortical group's segment in the pie chart is significantly larger for gaps ≥ 2 mm, while the bicortical group shows none exceeding 2 mm.

3: Pie Chart of Percentage of Cases with Lingual Gap :



Secondary Outcomes

Complications:

The monocortical group had one case that developed a mild infection at the site of surgery that was easily managed with antibiotics along with improved oral hygiene.

There were no hardware failures or malocclusions detected in either group at the 4-week follow-up.

Functional Recovery:

In the bicortical group, mouth opening at 4 weeks averaged 36 ± 5 mm and in the monocortical group, average mouth opening at 4 weeks was 38 ± 4 mm ($p = 0.1$).

At day 7, there was a marginal decrease in pain scores (at 10-point visual analog scale) in the bicortical group (mean 3.2 ± 1.0 versus the monocortical group (mean 4.0 ± 1.3); however, the difference was not statistically significant ($p = 0.08$).

DISCUSSION**Principal Findings**

This study is a randomized clinical trial that shows that bicortical screw fixation substantially decreases postoperative lingual gap in patients with isolated symphysis or parasymphysis fractures associated with bilateral condylar fractures treated conservatively. The lingual gap of the bicortical group was reduced to about 0.29 mm, which is much less than 3.40 mm found in the monocortical group ($p < 0.001$). These results indicate that the stability of lingual splaying is limited when both cortices are engaged.

Comparison with Existing Literature

Previous biomechanical and finite element studies indicated that bicortical fixation can provide better resistance to rotational and torsional forces in anterior mandibular fractures [1, 2]. This ongoing talk has been regarding the prolonged risk of lingual structures or neurovascular bundles injury with longer screws [3]. During our study, we saw no significant issues associated with screw length. This is in accordance with current clinical reports of the ability of experienced surgeons to utilize adequate preoperative imaging to safely perform bicortical fixation [4, 5].

Similarly, miniplates for mandibular fracture fixation, are studied to investigate the number of plates and screw positions required for stability. [6,7]. A well-accepted approach for symphysis and parasymphysis

fractures has been using two plates, one on the tension band region and the other on the inferior border. These results confirm the proposition that screw engagement in both of these plates at one or more cortices gives additional fracture fixation [8, 9].

Clinical Implications

The very small lingual gap in the bicortical group may imply that bicortical fixation may be advantageous in certain situations in which the bilateral condylar fractures are treated conservatively. As the posterior segment is rigid, condylar stability relies on the rigidity of this segment; hence, there is a dependency of maintenance of overall mandibular continuity on the minimal lingual splaying. It might lessen the chance of further complications such as malocclusion or nonunion [10].

Limitations

Single Center Design: Since the study had included a single tertiary care center, generalizability of the findings may be limited.

Short Follow-up Period: Lingual gap at one week postoperatively was evaluated. Though early healing stability is important, longer follow-up may be needed to determine functional outcomes and potential delaying complications.

Inadequate Power: With powers sufficient for detecting a difference in lingual gap, a larger multicenter trial could yield a more informative conclusion regarding functional outcome and rare complications.

Future Directions

Future work should include longer follow-up intervals that could demonstrate such parameters as bone healing, hardware longevity, maximum mouth opening, occlusal stability and patient-reported outcomes. Finally, multicenter, larger sample size trials would corroborate these findings and may assist developing standardized protocols for mandibular fracture management with or without bilateral condylar fracture.

CONCLUSION

This prospective randomized clinical trial shows that the bicortical fixation of the symphysis and parasymphysis fractures in the treatment of the bilateral condylar fractures is superior to the monocortical fixation. Underlines the mechanical advantage of engaging both the buccal and lingual cortices in comparison to the bicortical group in which the significantly lower lingual gap was observed. Bicortical fixation with no major complications and minimal increase in the risk of morbidity related to hardware appears to be a safe and effective option. These results need to be validated by further large-scale, multicenter studies of an extended follow-up period to refine best practice guidelines for management of mandibular fractures.

REFERENCES:

1. Ponvel K, Panneerselvam E, Balasubramanian S, Raja VK. Evaluation of labial versus labio-inferior lines of osteosynthesis using 3D miniplate for fractures of anterior mandible: A finite element analysis with a pilot clinical trial. *Chinese J Traumatol*. 2019;22(5):261-9.
2. Kaul V, Sethi H, Jindal N, Gupta S. Monocortical vs bicortical fixation in mandibular fractures: A systematic review of randomized clinical trials. *J Oral Biol Craniofac Res*. 2022;12(1):32-38.
3. Li L, Guo C, Zhang L, Wang J, Wang Z. Efficacy and safety of bicortical versus monocortical screw fixation in mandibular fractures: A meta-analysis of randomized controlled trials. *J Craniomaxillofac Surg*. 2021;49(8):700-706.
4. Raza M, Khan H, Mahmood K. Comparison of hardware stability between monocortical and bicortical screws in anterior mandibular fracture fixation. *Int J Oral Maxillofac Surg*. 2023;52(3):447-453.
5. Gao Y, Liu L, Wei X, Li B, Xu B. Complications in bicortical screw fixation for mandibular fractures: A retrospective clinical study. *J Stomatol Oral Maxillofac Surg*. 2022;123(4):e659-e664.
6. Wang J, Li P, Shen S, Zhang Y, Zhao Y. Management of bilateral condylar fractures with various fixation methods: A prospective cohort study. *Oral Surg Oral Med Oral Pathol Oral Radiol*. 2020;129(4):349-355.
7. Nair P, Babu B, Chattopadhyay PK, Abraham R. Comparative analysis of monocortical vs bicortical fixation in mandibular angle fractures. *Br J Oral Maxillofac Surg*. 2021;59(7):807-812.
8. Qiu S, Liu Y, Tan X, Jiang X. Clinical outcomes of monocortical and bicortical screw fixation in the management of symphysis mandibular fractures. *J Dent Sci*. 2019;14(4):422-428.
9. Zhao Y, Chen C, Yang X, He Y, Zhu S. Monocortical miniplate vs bicortical plate fixation in anterior mandibular fractures: A randomized clinical trial. *J Oral Maxillofac Surg*. 2020;78(6):1032-1039.
10. Kim YK, Hwang DS, Jang HU. Stability and complications of monocortical vs bicortical osteosynthesis in mandibular fractures: A systematic review. *Int J Oral Maxillofac Surg*. 2023;52(2):218-225.
11. Park JH, Kim JW, Kim MR. The effect of screw length on the stability of mandibular fracture fixation: A biomechanical analysis. *PLoS One*. 2019;14(9):e0222252.
12. Lima J, Soares M, Santos B, Cardoso T, Teles R. Postoperative stability of monocortical vs bicortical screws in mandibular symphysis fractures: A cohort study with 1-year follow-up. *Int J Oral Maxillofac Surg*. 2022;51(10):1317-1323.
13. Al-Moraissi EA, Ellis E 3rd. Is there a difference in stability or complications between monocortical and bicortical fixation in mandibular fractures? A systematic review and meta-analysis. *J Oral Maxillofac Surg*. 2019;77(8):1731-1740.
14. Goyal M, Gambhir S, Kaur G, Sharma A. Outcomes of miniplate osteosynthesis in mandibular parasymphysis fractures with concurrent condylar fractures: A clinical study. *J Clin Diagn Res*. 2020;14(9):ZC05-ZC09.

15. Patel K, Williams MD, Shah A. Comparative evaluation of closed vs open reduction of bilateral condylar fractures combined with anterior mandibular fracture management. *Int J Oral Maxillofac Surg.* 2021;50(12):1606-1612.
 16. Chen X, Wang X, Li S, Zou D. Finite element analysis comparing monocortical and bicortical fixation in mandibular symphyseal fractures. *Comput Methods Biomech Biomed Engin.* 2022;25(11):1247-1255.
 17. Tran H, Ho D, Luong H, Nguyen T. Bicortical screw fixation reduces lingual splaying in anterior mandibular fractures: A prospective clinical trial. *Oral Maxillofac Surg.* 2021;25(4):529-535.
 18. Sharma M, Ali I, Singh R. Effects of screw design and placement on stress distribution in mandibular fractures: A comparative finite element study. *J Stomatol Oral Maxillofac Surg.* 2023;124(1):101297.
 19. Wu S, Chen Y, Zhao E, Liu X. Mandibular fracture fixation: A review of current concepts and future trends. *Plast Reconstr Surg Glob Open.* 2022;10(4):e4273.
 20. Reddy LV, Singh G. Evolving concepts in maxillofacial trauma care: Minimally invasive approaches and rigid fixation. *Oral Maxillofac Surg Clin North Am.* 2023;35(2):261-275.
 21. Park JH, Kim Y. Management of condylar fractures: An update of current literature and clinical guidelines. *J Craniofac Surg.* 2022;33(6):1841-1846.
 22. Kumar G, Raja JV. Conservative vs surgical treatment of bilateral condylar fractures in adults: A systematic review and meta-analysis. *J Oral Biol Craniofac Res.* 2019;9(4):360-367.
 23. Ahmed N, Malik S, Qureshi A. Evaluation of monocortical miniplate fixation in mandibular fractures with emphasis on bite force recovery. *J Stomatol Oral Maxillofac Surg.* 2021;122(6):e327-e332.
- Delgado DA, Lambert HW, Linberg AL. Radiographic outcomes of bicortical screw fixation in mandibular angle fractures: A prospective analysis. *J Craniofac Surg.* 2020;31(6):1747-1751